

Review

Investigating the Effect of Immediate Loading of Implants Planted in the Cavities of Freshly Extracted Teeth

Elshan Bargahi¹, Amir Nouri², Mojtaba Esmailpour Roshan³

¹Doctor of Dental Surgery, Faculty of Dentistry, Tabriz University of Medical Science, Tabriz, Iran

²Bachelor of Urban Planning, Red Crescent Organization of Tabriz Province, Iran

³Doctor of Veterinary Medicine, Faculty of Veterinary Medicine, Islamic Azad University, Garmsar, Iran

*Correspondence to: Elshan Bargahi, Doctor of Dental Surgery, Faculty of Dentistry, Tabriz University of Medical Science, Tabriz, Iran; Email: Rashmin_ais@yahoo.com

Received: Sep 28th, 2022; Accepted: Oct 06th, 2022; Published: Oct 19th, 2022

Citation: Bargahi E, Nouri A, Roshan ME. Investigating the effect of immediate loading of implants planted in the cavities of freshly extracted teeth. *Dent Open A Open J.* 2022; 1(1): 19-25.

ABSTRACT

Background and Purpose

The benefits of immediate implant loading, such as saving time, immediate function, and patient satisfaction, have caused the desire to implement it to increase day by day. The aim of this study is immediate loading in dental implants.

Analysis Method

The search was done in PubMed, Embase, Blackwell Synergy, Sciondirect, Google Scholar, Google and Yahoo and related English books were also used. Keywords implant, immediate loading, early loading, delayed loading, occlusal loading and primary stability were used for searching. Factors affecting the success of immediate implant loading include patient selection, bone quality, dimensions, microstructure and macroscopic structure of the implant, surgeon's skill, initial stability and control of occlusal forces, and principles of prosthetics.

Findings

Regardless of the type of implant and its surface characteristics, immediate loading in the front of the mandible is predictable (90%-100% success). There is limited evidence on the success of immediate maxillary loading in partially edentulous individuals. Most of the studies are retrospective and lack a control group.

Conclusion

The anatomical location of the implant, the design of the implant and the principles of prosthetics are key factors to ensure success. Before the widespread use of this method, long-term prospective studies should be done.

Keywords: *Implant, Immediate loading, Early loading, Delayed loading, Occlusal loading, Initial stability.*

INTRODUCTION

High success¹⁻⁴ and advantages such as not needing to grind adjacent teeth and preventing alveolar bone loss⁵ have caused the use of dental implants to increase day by day. Often, to achieve successful osseointegration, it is recommended to follow the protocol provided by Branemark⁶, the recovery period of three months for the lower jaw and four to six months for the upper jaw is uncomfortable for the patient and often requires the construction of temporary prostheses that they do not have implant support, which makes it necessary.

Immediate loading has many advantages, including the elimi-

nation of the need for the second stage of surgery, the maturation of soft tissue before making the final prosthesis (preserving the gums and interdental papillae and as a result, better aesthetics), splinting the implants to each other by the temporary prosthesis and not needing He pointed out the use of temporary mobile prostheses that bring comfort, function, stability, better speaking and patient satisfaction.⁷

Immediate loading is defined as follows: implant loading using a temporary prosthesis in the same surgical session or a short period after surgery (usually up to three days). If loading takes place between one and three weeks after surgery, it is called "early loading".⁷

Review

Due to the mentioned advantages, many attempts were made to load the implant with a short distance after its placement.

Although progress in implant design and better understanding and control of forces has made immediate loading possible, achieving predictable results depends on following principles. The purpose of this article is to discuss the factors that can affect the success of immediate implant loading.

ANALYSIS METHOD

Search in Pubmed, Embase, Blackwell Synergy, Sciondirect, Google Scholar, Google and Yahoo from 1970-2020 was done and related English books were also used. The keywords implant, immediate loading, early loading, delayed loading, occlusal loading and initial stability were used. In the available articles and books, the factors influencing the success of immediate implant loading including patient selection, bone quality, dimensions and characteristics of the implant, surgical method, initial stability and control of occlusal forces and prosthetic principles were investigated.

FINDINGS

Several studies reported the achievement of osseointegration and high treatment success (more than 95%) using the immediate loading method⁸⁻¹⁴, promising results were also obtained with early loading. Just looking at the type of implant and its surface features and the design of the prosthesis is predictable. The evidence regarding edentulous upper jaw and semi-edentulous patients is limited, but these evidences have also shown the high success of immediate loading.¹⁵⁻¹⁶

For immediate loading with a fixed implant-based prosthesis, it was initially suggested that additional implants be placed for immediate loading so that the patient can benefit from the prosthesis while the main implants go through their healing period.¹⁷ Nowadays, it is recommended to use at least four implants in the lower jaw and five to eight implants in the upper jaw for immediate loading with a fixed prosthesis in a completely edentulous arch¹⁵, while some studies have shown that three implants in the lower jaw It is enough¹⁸, but in this case, the loss of an implant causes the possibility of prosthetic treatment to disappear.

In the immediate loading of semi-edentulous people and single-tooth implants, it is a matter of disagreement whether the fully functional prosthesis has an effect on the success of the prosthesis or not. The role of occlusion has not yet been fully determined.¹⁵

In immediate implant loading with overdenture, osseointegration can be achieved without splinting the implants. In addition, the type of dentition in the opposite jaw (denture, fixed prosthesis or natural teeth) has no effect on success. Usually, due to the change of soft tissue following surgery, there will be a need for relining (lining).¹⁵

DISCUSSION

Most studies have reported similar success for immediate loading compared to the two-stage method¹⁹⁻²¹, but this does not mean abandoning the delayed loading method. Several factors can affect the results of instant loading. These factors can be divided into four categories: factors

related to surgery (including initial stability and surgical technique), factors related to the patient (including the quantity and quality of bone and how to repair the wound), factors related to the implant (including its design and surface characteristics) and factors examined the occlusal (including the quantity and quality of forces and implant prosthesis design).

FACTORS RELATED TO SURGERY

When one-stage implant placement with immediate loading is considered, initial stability and minimization of micromovement before completing osseointegration are necessary for success. The initial stability is the most important and decisive factor in the success of immediate loading. The quantity and quality of bone, surgical technique and implant design (because it is threaded and having a rough surface) affect the initial stability²²⁻²⁵, to evaluate the stability of the implant. Different techniques such as radiography, tapping on the implant with a metal tool (Tapping), periostest, reverse torque and resonance frequency have been used.

Disadvantages of radiography technique are: Receiving radiation, the time it takes for radiographic evidence to appear, repeatability and non-standard. Clinical assessment of tooth looseness is provided and is not specific for implants²⁶, reverse torque can also be measured once and is used in studies. Many variables affect it.²⁷ It has been shown that the success of implants with different sizes depends on the final torque when they are placed.²⁸ Although initial stability is important, the high strain caused by high torque (45 to Sixty newtons per centimeter) causes bone microfracture. The result will be an increase in bone remodeling.⁷ Placement torque of about²⁹⁻⁴⁰ Ncm during surgery is useful for predicting the level of initial stability.

Osstell is a commercial device for measuring resonance frequency. The results are between six and nine kilohertz, which are converted into numbers between one and one hundred. The numerical values of the device are called Implant Stability Quotient (ISQ). Although previous studies considered this method suitable for evaluating osseointegration changes.³⁰⁻³¹

Recent studies have only confirmed the ISQ value of 57-70 to show the existence of initial stability and have questioned the value of this method in determining the nature of the connection of the implant to the bone and the changes of implant stability over time.³²

The tolerable amount of micro-motion has been reported between 50 and 150 micrometers³³, implant design, loading method, prosthesis design and diet are effective on the amount of micro-motion. Depending on the design and surface of the implant, the amount of tolerable micro-movement that does not endanger the osseointegration changes.

Surfaces covered with fine calcium phosphate tolerate more movement in this range. If the implants are splinted by a prosthesis, the micro-motion will be reduced.³³ Thermal injuries and micro fractures during implant placement are among the factors that cause trauma and can lead to bone necrosis and the subsequent formation of a fibrous capsule around the implant³⁴, drill design, drill speed, drill sharpness, bone

Review

removal rate, depth Osteotomy and thickness of cortical bone are effective in the amount of generated heat. It causes more effective drilling, without a significant increase in heat³⁶, drilling systems with internal cooling produce more heat.³⁷

Atraumatic surgery is possible by accurately determining the location of the implant. By using a precise surgical template, the need for wide flaps is eliminated and even flapless surgeries are possible³⁸, in the anterior region of the jaw, if there is to be immediate loading, the implant should preferably include the opposite cortical surface, in the posterior regions of the upper jaw due to the very thinness of the sinus floor, and in the lower jaw due to the presence of the neural canal in the cortical bone. It is not possible in the floor of the sinus and the wall of the neural canal.²⁹

For immediate loading in soft bone, a modified surgical technique should be used as follows³⁴:

- 1) No pretapping
- 2) Not doing Countersink or minimizing its amount
- 3) Reducing the diameter of the drill
- 4) Using implants with a larger diameter or longer length
- 5) Bicortical stabilization

PATIENT RELATED FACTORS

The amount of bone contact with the implant is less in bones with low density²⁹, the success rate of immediate placement behind the upper jaw is reported to be 66%. and diameter, the position of implants with longer length (A-P, the distance between the center of the most anterior implant to the most distal implant) and the reduction of the cantilever becomes more important. is ten mm, the delayed loading method should be used²⁹, of course, initial stability plays a more important role in the success of immediate loading than the jaw arch under treatment, and under ideal conditions, the treatment results will be similar in both jaws.¹⁴

The result of bone grafting depends on sufficient blood supply and lack of micromovement. The result of the work is more predictable when the soft tissue (or membrane) completely covers the graft. All of these make immediate loading dangerous for bone graft areas. The bone resulting from the graft is woven type and can be subjected to overloading²⁹, the graft materials cause less stability and less implant-bone contact³⁵, when the insufficient volume of the bone makes it necessary to place the graft, Placement of the implant and subsequent immediate loading after graft maturation.²⁹ Metabolic and systemic diseases disturb the recovery in the patient. In people who have an uncontrolled disease (such as diabetes), rickets resistant to vitamin D, osteoporosis, hyperparathyroidism, a history of radiotherapy, ongoing chemotherapy, and alcohol and drug addiction, immediate loading should not take place. In Sjogren's syndrome, the chance of treatment failure is also high. In smokers (those who smoke more than 20 cigarettes a day), the probability of failure in immediate loading is twice the normal rate. Although in old age, recovery is slow and medical problems become more, but age is

not considered as a risk factor for immediate loading.

Type 2 diabetes is not a risk factor for immediate loading. People with poor oral hygiene and uncooperative people (patients who come only when they have problems) are unsuitable for immediate loading.³⁹⁻⁴⁰

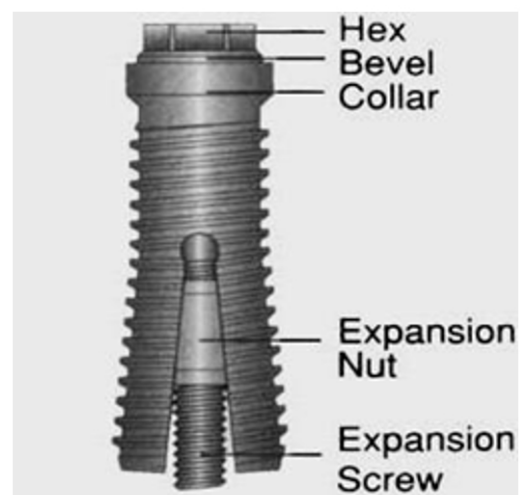
IMPLANT RELATED FACTORS

The design of the implant body must be very specific for immediate loading, because the implant requires maximum stability during placement, and the bone does not have time to grow inside the inner canals of the implant body or connect to a special surface. The effect of the implant design on the functional level is more important than its size.

From the same day of placement, the threaded implant has some bone in the depth of the groove. The initial stability of the threaded implant is more than the press-fit implant. The number, distance and direction of the threads are also effective on the size of the area. The more the number of threads, the less their distance and the deeper they are, the more functional space will be available for immediate loading. They are also deeper, but in terms of initial stability, it is superior to cylindrical types, which are known to compress the surgical area of the implant (especially its coronal area) during implant placement.⁴¹

Special designs have been presented to increase the initial stability. One of these cases is the Sargon implant, which is a type of expandable implant (Figure 1). If instability occurs in these implants, by removing the temporary prosthesis, the applied forces are removed for 16-18 weeks, and through additional expansion by twisting its specific screw on the implant, stability is established again¹³, in general, it should be It was noted that the number and position of the implant and issues related to the patient are more important than the design of the implant for the success of the treatment. No difference has been seen in the success of different types of implants.¹²

Figure 1: Sargon implant



The condition of the implant surface also affects the level of

Review

bone contact and lamellar bone formation. The rough surface has increased the amount of contact between the implant and the bone¹¹, increased the shear strength of the implant up to five times⁴² and It increases the initial stability⁴³⁻⁴⁴, the level of mineralization (Mineralization) and the speed of lamellar bone formation also increases with the increase of the roughness of the implant surface.

Implant success increases with hydroxyapatite coating⁴⁵, hydroxyapatite (HA) decreases the speed of bone remodeling during the application of occlusal forces, which causes an increase in the percentage of lamellar bone at the contact site of the implant bone⁴⁶, of course, with two surgeries No difference was observed in phase and delayed loading between implants with a surface covered with HA and without this surface coating⁴⁷, the maximum torque during implant placement in type four bone changes under the influence of the implant design, but in bones with better quality (type two). and 3) no difference is observed⁴⁸⁻⁴⁹, the design with a thread is more useful for immediate loading than the rough surface. The surface impregnated with hydroxyapatite shows its advantage in the initial period of restoration (weeks three to five).

OCCUSAL FACTORS

The control of functional forces is of particular importance to reduce the amount of micro-motion and as a result of the success of immediate loading. Pressure is equal to force divided by surface area.

Therefore, there are two ways to reduce it: reducing the force and increasing the level. Increasing the surface can be achieved by increasing the number of implants, increasing the dimensions of the implant and creating changes in the design and characteristics of the implant surface.

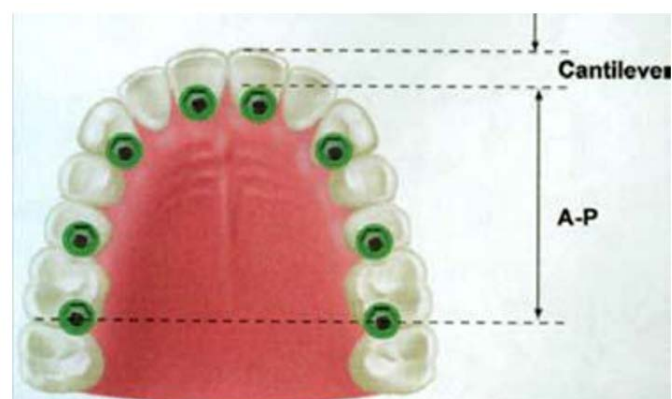In the articles that reduce the success of implants with immediate loading, a small number of implants have been used to support the prosthesis. The ratio of prosthetic units to the number of implants for immediate loading should be at least 1.4 in the upper jaw and 1.5 in the lower jaw (12-8 implants in the upper jaw and 9-5 implants in the lower jaw). The number of implants required in the upper jaw is to compensate for its lower bone density and the outward direction of the applied forces in the arch of the upper jaw. If this ratio is more than two, the failure rate will be high due to the increase of micron movements²⁹, Of course, it is possible to adjust these values according to the opposite occlusion, implant diameter, bone quality, implant design and other pressure factors.¹²

In people who have lost a number of their teeth, it is not always possible to increase the number of implants due to reasons such as insufficient space. By choosing thicker implants, the functional level can be increased. The effect of increasing the diameter in reducing the possibility of applying excessive force to the bone crest is more important than the length. Of course, in order to prevent overloading, the diameter of the implant is valuable when the minimum length is provided for initial stability. In addition, increasing the diameter helps to engage the lingual cortical plate by the implant and this also increases the initial stability.^{7,29}

For immediate loading, the length of the implant is very important, especially in bones that have low quality. and when one area is undergoing remodeling and another area is stable, increasing the length makes it possible for the stable areas to help maintain the implant²⁹, increasing the length of the implant increases its lifespan.¹⁰ For immediate loading in Wide platform, it is necessary to have a minimum length of 8.5 mm and in normal types, a minimum length of 10 mm for the implant. When the length of the implant is less than ten millimeters, the rate of failure in immediate loading increases up to 50%.²⁹ The habits of the patient, the position of the implant, the presence of the cantilever, the direction of the occlusal forces, the location of the occlusal contacts and the patient's diet are effective on the force exerted on the bone-implant junction. In parafunction (such as grinding teeth) and (the amount and duration of applying force is very high and the direction of applying force is mostly horizontal⁵⁰, it has been shown that 75% of failures in immediate loading occur in people who have grinding teeth⁵¹, parafunction causes loosening of the abutment screw, loss of the prosthesis retainer due to cement washing and fracture of the temporary prosthesis used for immediate loading, which each If this happens, the remaining implants will be under more load²⁹, of course, the effect of parafunction on bone loss around the implant has not been proven⁵², immediate loading should not be done in completely edentulous people who have severe parafunction.²⁹ In completely edentulous people, the position of the implants is as important as their number. The mandible is divided into three main regions (canine to canine and two posterior regions) and the upper jaw is divided into four regions (two canines and two posterior regions). At least one implant should be placed in each area for immediate loading of the full implant support prosthesis. If the forces are high, a fifth area is added to the upper jaw, and this added area is the area of the incisors.¹

The maximum anterior and posterior distance (A-P) should be provided (Figure 2).

Figure 2: The maximum anterior-posterior distance is desirable

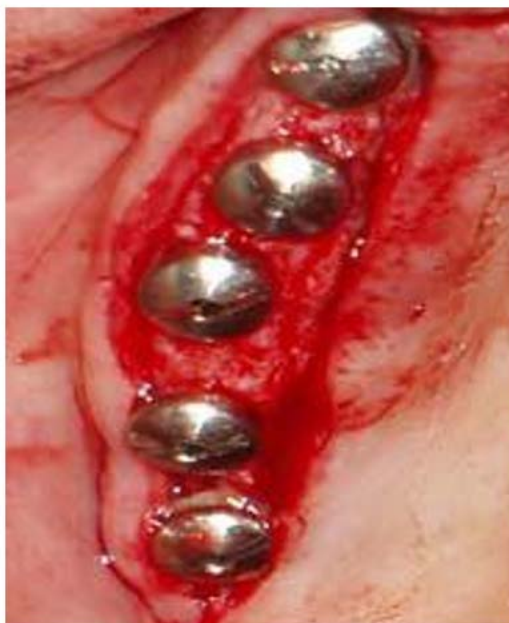

If the adjacent implants are not in a straight line, less pressure will be transferred to the bone connection of the implant⁴⁰ (Figure 3). Cross arch support is also important.

Review

Splinted implants reduce the pressure in the entire implant support system. The problem of mandibular flexure in splinting with temporary acrylic prosthesis, especially if there are three or more pontics and the length of the area for bending, will not be a cause for concern.¹

Figure 3: Implants should not be on a straight line as much as possible



The temporary prosthesis made for immediate loading should not have a posterior cantilever. Because the posterior cantilever is not important from the point of view of beauty, and due to the high welding forces in the posterior region, it will have a destructive effect on the implants. In addition, these temporary prostheses should be attached with permanent cement because if the cement is lost in a part of the prosthesis, a cantilever will appear.²⁹

The offset force causes the accumulation of osteoclasts and inflammatory cells at the border of the implant and the bone. It is important to try to apply force in the direction of the longitudinal axis of the implant, especially in conditions where the height of the crown is high (vertical cantilever).⁵³

Flat occlusal surface in the posterior area reduces the risk of applying horizontal forces.²⁹

When immediate loading is done in people who have lost only a few teeth, the amount of force applied to the implant is reduced by eliminating occlusal contacts. Beauty can be achieved without establishing occlusal contacts. Non functional immediate teeth, which lack occlusal contact, reduce the risk of parafunction.

In completely toothless people, the effect of parafunction can be removed by making an overdenture that is removed at night.

It is possible to benefit from the role of the pressure breaker of the attachment system to reduce the transmission forces to the implant when the prosthesis is in function.²⁹

During the immediate loading period, until the temporary prosthesis is replaced with the permanent prosthesis, the diet should be limited to soft foods (such as fish and pasta). Foods that require a lot of boiling force can cause the temporary prosthesis to break or the cement to be washed away in a part of the prosthesis, which in both cases will cause destructive forces to enter the implants.²⁹

The general considerations of temporary prostheses to minimize problems during immediate loading can be specified as follows:^{39, 12}

- 1) The temporary prosthesis must splint the implants together, with the exception of single-tooth implants.
- 2) The passive fit type of screw is preferable to the cemented type due to the ability to open and close easily between sessions and the strength of the screw.
- 3) During the recovery period (four months for the lower jaw and six months for the upper jaw), the temporary prosthesis should never be removed. (Using permanent cement)
- 4) If the distance between the implants is large, the acrylic will bend and cause micromotion. Metal substructure is recommended in these cases.
- 5) Cantilever should be avoided as much as possible.

CONCLUSION

Despite the advantages of immediate loading and the patient's demand to benefit from the results of the treatment as quickly as possible, such a thing should not be done without considering all aspects, because the result will be the failure of the treatment and the implant, and ultimately increase the cost and patient dissatisfaction. Preferably, a decision should be made about whether immediate loading will be done or not, before placing the implant. In this case, with a specific program, the necessary conditions for the success of the treatment can be provided.

REFERENCES

1. Adell R, Lekholm U, Rocker B, Branemark PI. A 15 years study of osseointegrated implants in the treatment of edentulous jaw. *Int J Oral Surg.* 1981; 10(6): 387-416. doi: [10.1016/s0300-9785\(81\)80077-4](https://doi.org/10.1016/s0300-9785(81)80077-4)
2. Lazzara R, Siddiqui AA, Binon P, et al. Retrospective multicenter analysis of 3i endosseous dental implants placed over a five year period. *Clin Oral Implants Res.* 1996; 7(1): 73-83. doi: [10.1034/j.1600-0501.1996.070109.x](https://doi.org/10.1034/j.1600-0501.1996.070109.x)
3. Buser D, Mericske Stern R, Bernard JP, Behneke A, Behneke N, Hirt HP, et al. Long term evaluation of non submerged ITI implants. Part 1: 8 years life table analysis of a prospective multi center study with 2359 implants. *Clin Oral Implants Res.* 1997; 8(3): 161-172. doi: [10.1034/j.1600-0501.1997.080302.x](https://doi.org/10.1034/j.1600-0501.1997.080302.x)

Review

4. Lekholm U, Gunne J, Henry P, Higuchi K, Linden U, Bergstrom C, et al. Survival of Branemark implant in partially edentulous jaws: A 10 year prospective multicenter study. *Int J Oral Maxillofac Implants.* 1999;14(5): 639-45.
5. Misch CE. Dental implant Prosthetics. 1st ed. St Louis: Mosby ; 2005, 1-17.
6. Branemark PI, Hansson BO, Adell R, Breine U, Lindstrom J, Hallen O. et al. Osseointegrated implants in the treatment of the edentulous jaw. Experience from a ten year period. *Scand J Plast Reconstr Surg.* 1977; 16(suppl): 1-132.
7. Misch CE. Dental Implant Prosthetics. 1st ed. St Louis: Mosby; 2005, 531-568.
8. Glauser R, Rée A, Lundgren AK. Immediate occlusal loading of Branemark implants applied in various jaw bone regions: A prospective 1 year clinical study. *Clin Impl Dent Rel Res.* 2001; 3(4): 204-213. doi: [10.1111/j.1708-8208.2001.tb00142.x](https://doi.org/10.1111/j.1708-8208.2001.tb00142.x)
9. Chaushu G, Beals DW, Larsen PE. Immediate loading of single tooth implants: immediate vs non immediate implantation. A clinical report. *Int J oral Maxillofac impl.* 200;16(2): 267-272.
10. Wohrle P. Single tooth replacement in aesthetic zone with immediate provisionalization: fourteen consecutive case reports. *Prac Perio Aesth Dent.* 1998; 10(9): 1107-1114.
11. Sagara M, Akagawa Y, Nikai Hand Tsury H. The effects of early occlusal loading in one stage titanium alloy implants in beagle dogs: A pilot study. *J Prosth Dent.* 1993; 69(3): 281-288. doi: [10.1016/0022-3913\(93\)90107-y](https://doi.org/10.1016/0022-3913(93)90107-y)
12. Degidi M, Piatelli A. Immediate functional and non functional loading of dental implants: A 2 to 60 month follow up study of 646 titanium implants. *J periodontal.* 2003; 74(2): 225-241. doi: [10.1902/jop.2003.74.2.225](https://doi.org/10.1902/jop.2003.74.2.225)
13. Jo YH, Hobo PK, Hobo S. Freestanding and multiunit immediate loading of the expandable implant: An up-to-40-month prospective survival study. *J Prosthet Dent.* 2001; 85(2): 148-155. doi: [10.1067/mpr.2001.113355](https://doi.org/10.1067/mpr.2001.113355)
14. Gapski R, Wang HL, Mascarenhas P, Lamg NP. Critical review of immediate implant loading. *Clin Oral Impl Res.* 2003; 14(5): 515-527. doi: [10.1034/j.1600-0501.2003.00950.x](https://doi.org/10.1034/j.1600-0501.2003.00950.x)
15. Attard NJ, Zarb GA. Immediate and early implant loading protocols: A literature review of clinical studies. *J Prosthet Dent.* 2005; 94(3): 242-258. doi: [10.1016/j.prosdent.2005.04.015](https://doi.org/10.1016/j.prosdent.2005.04.015)
16. Avila G, Galindi P, Rios H, Wang HL. Immediate implant loading: Current status from available literature. *Implant Dent.* 2007; 16(3): 235-245. doi: [10.1097/ID.0b013e3180de4ec5](https://doi.org/10.1097/ID.0b013e3180de4ec5)
17. Tarnow DP, Emtiaz S, Classi A. Immediate loading of threaded implants at stage 1 surgery in edentulous arches: Ten consecutive case reports with 1 to 5 year data. *Int J Oral Maxillofac Implants.* 1997; 12(3): 319-324.
18. Engstrand P, Grondahl K, Ohnell LO, Nilsson P, Nannmark U, Branemark PI. Prospective follow up study of 95 patients with edentulous mandibles treated according to the branemark Novum concept. *Clin Implants Dent Relat Res.* 2003; 5(1): 3-10. doi: [10.1111/j.1708-8208.2003.tb00176.x](https://doi.org/10.1111/j.1708-8208.2003.tb00176.x)
19. Colomina LE. Immediate loading of implant fixed mandibular prostheses: A prospective 18 month follow up clinical study – preliminary report. *Implant Dent.* 2001; 10(1): 23-29. doi: [10.1097/00008505-200101000-00008](https://doi.org/10.1097/00008505-200101000-00008)
20. Cooper L, Felton DA, Kugelberg CF, et.al. A multicenter 12 month evaluation of single tooth implants restored 3 weeks after 1 stage surgery. *Int J Oral Maxillofac Implants.* 2001; 16(2): 182-192.
21. Ganeles j, Rosenberg MM, Holt RL, Reichman LH. Immediate loading of implants with fixed restorations in the completely edentulous mandible: Report of 27 patients from a private practice. *Int J Oral Maxillofac Implants.* 2001; 16(3): 418-426.
22. Romanos GE. Present status of immediate loading of oral implants. *J Oral Implantol.* 2004; 30(3): 189-197. doi: [10.1563/1548-1336\(2004\)30<189:PSOIL0>2.0.CO;2](https://doi.org/10.1563/1548-1336(2004)30<189:PSOIL0>2.0.CO;2)
23. O'Sullivan D, Sennerby L, Meredith N. Measurements comparing the initial stability of five designs of dental implants: A human cadaver study. *Clin Implant Dent Relat Res.* 2000; 2(2): 85-92. doi: [10.1111/j.1708-8208.2000.tb00110.x](https://doi.org/10.1111/j.1708-8208.2000.tb00110.x)
24. Sunden S, Grondahl K, Grondahl HG. Accuracy and precision in the radiographic diagnosis of clinical instability in Branemark dental implants. *Clin Oral Implants Res.* 1995; 6(4): 220-226. doi: [10.1034/j.1600-0501.1995.060404.x](https://doi.org/10.1034/j.1600-0501.1995.060404.x)
25. Adell R, Lekholm U, Branemark PI. Surgical procedures. In: Branemark PI, Zarb G, Albrektsson T. *Tissue Integrated Prostheses: Osseointegration in Clinical Dentistry.* 1st ed. Chicago: Quintessence Publ Co; 1985, 211-32.
26. Schulte W, Lukas D. Periotest to monitor osseointegration and to check the occlusion in oral implantology. *J Oral Implantol.* 1993; 19(1): 23-32.
27. Sullivan DY. Prosthetic considerations for the utilization of osseointegrated fixtures in the partially edentulous arch. *Int J Oral Maxillofac implants.* 1986; 1(1): 39-45.
28. Froum SJ, Simon H, Cho SC, Elian N, Rohrer MD, Tarnow DP. Histologic evaluation of bone-implant contact of Immediately loaded transitional implants after 6 to 27 months. *Int J Oral Maxillofac Implants.* 2005; 20(1): 54-60.
29. Misch CE, Wang HL, Misch CM. Rationale for application of immediate load in implant dentistry: Part II. *Implant Dent.* 2004; 13(4): 310-321.
30. Meredith N. A review of non-destructive test methods and their application to measure the stability and osseointegration of bone anchored endosseous implants. *Crit Rev Biomed Eng.* 1998; 26(4): 275-291. doi: [10.1615/critrevbiomedeng.v26.i4.20](https://doi.org/10.1615/critrevbiomedeng.v26.i4.20)

Review

31. Friberg B, Sennerby L, Lindčn B, Grndahl K, Lekholm U. Stability measurements of one-stage Branemark implants during healing in mandibles. A clinical resonance frequency analysis study. *Int J Oral Maxillofac Surg.* 1999; 28(4): 266-272.
32. Huwiler MA, Pjetursson BE, Bosshardt DD, Salvi GE, Lang NP. Resonance frequency analysis in relation to jawbone characteristics and during early healing of implant installation. *Clin Oral Impl Res.* 2007; 18(3): 275-280. doi: [10.1111/j.1600-0501.2007.01336.x](https://doi.org/10.1111/j.1600-0501.2007.01336.x)
33. Moncler SS, Salama H, Reingewirtz Y, Dubruille JH. Timing of Loading and effect of micromotion on bone– dental implant interface: Review of experimental literature. *J Biomed Mater Res.* 1998; 43(2): 192- 203. doi: [10.1002/\(sici\)1097-4636\(199822\)43:2<192::aid-jbm14>3.0.co;2-k](https://doi.org/10.1002/(sici)1097-4636(199822)43:2<192::aid-jbm14>3.0.co;2-k).
34. Eriksson A, Alberktsson T, Grane B, McQueen D. Thermal injury to bone: A vital microscopic description of heat effects. *Int J Oral Surg.* 1982;11(2):115-121. doi: [10.1016/s0300-9785\(82\)80020-3](https://doi.org/10.1016/s0300-9785(82)80020-3)
35. Haider R, Watzek G, Plenk H. Effects of drill cooling and bone structure on IMZ implant fixation. *Int J Oral Maxillofac Implants.* 1993; 8(1): 83-91.
36. Brisman DL. The effect of speed, pressure and time on bone temperature during the drilling of implant sites. *Int J Oral Maxillofac Implants.* 1996;11(1): 35-37.
37. Eriksson AR, Alberktsson J. Temperature threshold levels for heat induced bone tissue injury: A vital microscopic study in the rabbit. *J Prosthet Dent.* 1983; 50(1): 101-107. doi: [10.1016/0022-3913\(83\)90174-9](https://doi.org/10.1016/0022-3913(83)90174-9)
38. Ericsson I, Nilson H, Lindh T, Nilner K, Randow K. Immediate functional loading of branemark single tooth implants. An 18 months clinical pilot follow up study. *Clin Oral Impl Res.* 2000;11(1): 26-33. doi: [10.1034/j.1600-0501.2000.011001026.x](https://doi.org/10.1034/j.1600-0501.2000.011001026.x)
39. Lekholm U. Immediate / early loading of oral implants in compromised patients. *Periodontol.* 2003; 33(1): 194-203. doi: [10.1046/j.0906-6713.2003.03316.x](https://doi.org/10.1046/j.0906-6713.2003.03316.x)
40. Friesen B. What are the critical success factors for anterior single-tooth immediate-load implants? *Point of Care. JCDA [Serial Online]* 2005; 71(8): 550-551. Website: www.cda-adc.ca/jcda
41. Romenos G, Tok CG, Siar CH, et al. Peri implant bone reactions to immediately loaded implants: An experimental study in monkeys. *J Periodontol.* 2001; 72(4): 506-511. doi: [10.1902/jop.2001.72.4.506](https://doi.org/10.1902/jop.2001.72.4.506)
42. Li DH, Liu BL, Zou JC. Improvement of osseointegration of titanium dental implants by a modified sandblasting surface treatment: An in vivo interfacial biomechanics study. *Implant Dent.* 1999; 8(3): 289-294. doi: [10.1097/00008505-199903000-00014](https://doi.org/10.1097/00008505-199903000-00014)
43. Buser D, Schemk RK, Steinman S. Influence of surface characteristics on bone integration of titanium implants. A histomorphometric study in miniature pigs. *J Biomed Mater Res.* 1991; 25(7): 889-902. doi: [10.1002/jbm.820250708](https://doi.org/10.1002/jbm.820250708)
44. Brunski JB. Biomechanical factors affecting the bone dental implant interface: Review paper. *Clin Master.* 1992 Autumn; 10(3): 153-201. doi: [10.1016/0267-6605\(92\)90049-y](https://doi.org/10.1016/0267-6605(92)90049-y)
45. Lum LB, Beirne OR, Curtis DA. Histologic evaluation of hydroxylapatite coated versus uncoated titanium blade implants in delayed and immediately loaded applications. *Int J Oral Maxillofac Implants.* 1991; 6(4): 456-462.
46. Block MS, Kent JN, Kay SF. Evaluation of hydroxylapatite coated titanium dental implants in dogs. *J Oral Maxillofac Surg.* 1987; 45(7): 601-607. doi: [10.1016/0278-2391\(87\)90270-9](https://doi.org/10.1016/0278-2391(87)90270-9)
47. Evans GH, Mendez AJ, Caudill RF. Loaded and non loaded titanium versus hydroxyapatite coated threaded implant in the canine mandible. *Int J Oral Maxillofac Implants.* 1996; 11(3): 360-371.
48. Sirota C, Fiorellini J, Corso M. Immediate loading of implants with various coating in beagle dogs. *J Dent Res.* 1996; 75(6): 400-408.
49. Schnitman DA, Wohrle PS, Rubenstein JE, DaSilva JD, Wang NH. Branemark implants immediately loaded with fixed prostheses at implant placement: ten year results. *Int J Oral Maxillofac Implants.* 1997; 12(4): 495-503.
50. Misch CE. *Dental Implant Prosthetics*, 1st ed, St Louis: Mosby; 2005, 83-85.
51. Branemark PI, Engstrand P, Ohnell LO. Branemark Norum. A new treatment concept for rehabilitation of the edentulous mandible. Preliminary results from a prospective clinical follow up study. *Clin Impl Dent Rel Res.* 1999; 1(1): 2-16. doi: [10.1111/j.1708-8208.1999.tb00086.x](https://doi.org/10.1111/j.1708-8208.1999.tb00086.x).
52. Vidyasagar L, Apse P. Biological response to dental implant loading / Overloading. implant overloading: empiricism or science? *Baltic Dent and Maxillofac J.* 2003; 5(3): 83-89.
53. Misch CE. *Dental implant prosthetics*. 1 st ed. St Louis: Mosby; 2005, 252-265.