Gynecology and Obstetrics Open Access Open Journal

SOAOJ PUBLISHING

Review

Uterine Isthmocele (Niche after Cesarean Section)

Mohamed Nabih EL-Gharib, MBBCH, DGO, DS, MD*

Professor of Obstetrics and Gynecology, Faculty of Medicine, Tanta University, Tanta, Egypt

Correspondence to: Mohamed Nabih EL-Gharib; Professor of Obstetrics and Gynecology, Faculty of Medicine, Tanta University, Tanta, Egypt; Tel. +201117040040; E-mail: mohgharib2@hotmail.com

Received: February 16th, 2019; **Revised:** February 20th, 2019; **Accepted:** February 19th, 2019; **Published:** March 4th, 2019

Citation: EL-Gharib MN. Uterine isthmocele (Niche after cesarean section). *Gyne and Obste Open A Open J.* 2019; I(1): 13-16

Abstract

An isthmocele, also called a niche, cesarean scar defect, or cesarean scar dehiscence is a pouchlike defect of the anterior uterine isthmus at the site of a prior cesarean section. Its occurrence has been increased in the last years secondary to the increased incidence of cesarean section. Many patients with isthmocele are asymptomatic. The most frequent complaint relates to intermittent postmenstrual bleeding as the isthmocele functions as a reservoir collecting blood during menstruation, with irregular menses that can run for 2 to 12-days. Various sources have described isthmocele as a case of infertility, pain and dysmenorrhea. An isthmocele is typically diagnosed on transvaginal sonography, hysterosalpingography and hysteroscopy. Magnetic resonance tomography is useful to measure the thickness of the lower uterine segment, the profundity of the isthmocele. The treatment of isthmocele includes laparotomy, laparoscopy, hysteroscopy, vaginal repair, and several combined techniques with no statistically superior outcome noted in the literature. In that respect is no gold standard treatment for isthmocele.

Keywords: *Niche, Isthmocele, Uterine sacculations, Cesarean section complications.*

INTRODUCTION

An isthmocele, also called a niche, cesarean scar defect, cesarean scar dehiscence, uterine diverticulum, pouch, or sacculation. It is a pouchlike defect of the anterior uterine isthmus at the site of a prior cesarean section,[1] which was first described by Morris in 1995.[2]

An isthmocele is a man-made lake-like pouch defect in the anterior wall of the uterine isthmus located at the site of the previous cesarean scar. Therefore, the cesarean-induced isthmocele may lead to the occurrence of gynecologic symptoms such as abnormal uterine bleeding (AUB) secondary to intermittent passage of retained menstrual blood within the cesarean scar defect (CSD), pelvic pain, and sterility.[1,3]

The first scar defect ever reported was in 1975 when Stewart, et al who noted that preoperative historiography or pelvic arteriography might help with diagnosis and that the uterus could be saved by excision of the lower segment scar.[4] The worldwide prevalence of isthmoceles out of all cesarean sections ranges from 19% to 84%,[5] but this may be underrated because of asymptomatic patients and a lack of clinician awareness. Sonohysterography (SHG) identified a higher number of patients with isthmoceles (56%–78%) than transvaginal ultrasound (24%–69%) as noted by van der Voet et al.[6]

There is an increasing tendency for cesarean delivery worldwide. Although several obstetric complications such as placenta accreta, scar dehiscence, and ectopic scar pregnancy due to inappropriately heal uterine lower segment incision have been reported, gynecologic sequela are increasingly reported in the last decade.[7] It has been 30 years since the World Health Organization issued a statement warning about the high rate of cesarean sections and recommending a maximum 15% rate of surgical intervention.[8]

Despite this, the United States reported an increase of 50% in cesarean sections from 1996 to 2007;[9] and other nations such as Brazil reported an overall cesarean section rate of 45% and a private practice rate of 81%.[10]

In Egypt, the past decade has seen a precipitous growth in the prevalence of CS with the most recent Egypt Demographic and Health Survey (EDHS) documenting a CS rate of 52%, which suggests that cesarean delivery might be overused or used for inappropriate indications.[11]

In the UK the figure stands at barely over 26%, but in some countries more than half of births involve the procedure: in the Dominican Republic over 58% of babies are presented this way, while in Egypt the figure is 63% when looking just at births in institutional contexts.[12]

The relationship between different types of uterine closure and the prevalence of cesarean scar defects is unclear. Although the risk for a uterine scar defect was shown to increase in single layer myome-

trial closure compared with double-layer closure. Although the rate of large scar defects was doubled in singlelayer closure, this difference was not statistically significant. The lack of association between the closing technique and scar defect size could be caused by type II statistical error.[13]

SYMPTOMS

Many patients with isthmoceles are asymptomatic, and patients might consult with different physicians before the right diagnosis is found. The most frequent complaint relates to intermittent postmenstrual bleeding. The isthmocele functions as a reservoir collecting blood during menstruation, with irregular menses that can run for 2 to 12-days.[14]

Various sources have described isthmoceles as a case of infertility, stating deficient sperm motility and implantation.[15,16] Pain and dysmenorrhea are general symptoms common to numerous gynecologic causes. The relationship between isthmoceles and pain is not clear but could be linked to abnormal my ocontraction caused by physiological irregularities and continuous efforts of the uterus to evacuate the contents of the isthmocele. Wang et al found a significant relationship among dysmenorrhea, the breadth of the defect, and abnormal bleeding.[17]

DIAGNOSIS

An isthmocele is typically diagnosed on transvaginal sonography and appears as a wedge-shaped anechoic area with a depth of at least 1 mm and an indentation of the myometrium of at least 2 mm in the uterine isthmus at the cesarean section scar site.[16] Ultrasound is used to measure the depth and size (longitudinal) of the dehiscent scar and the thickness of the residual myometrium covering the dehiscence (Figure 1). The diagnosis of a cesarean scar defect can also be performed by direct visualization with hysteroscopy. On hysteroscopy, the defect is observed as a bulge on the anterior wall of the uterine isthmus (Figure 2).

Figure I. Ultrasonographic images of the uterus. The anechoic area in the anterior uterine wall was the uterine defect surrounded by thin residual myometrium

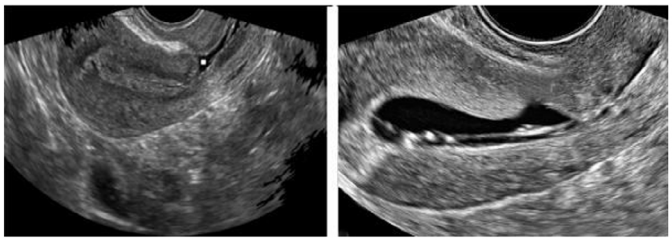

Figure 2. The hysteroscopic view of the niche

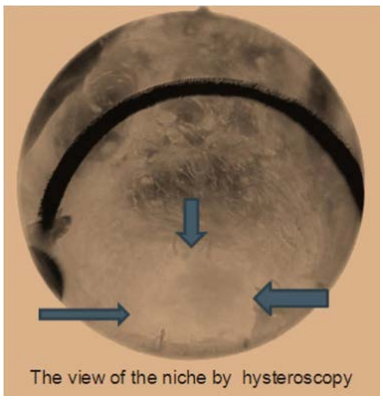

Hysterosalipigography can also help in the diagnosis of uterine niche as depicted in figure 3.

Figure 3. Anteroposterior and lateral view a of hysteroslapingram of the uterus showing the uterine scar diverticulum

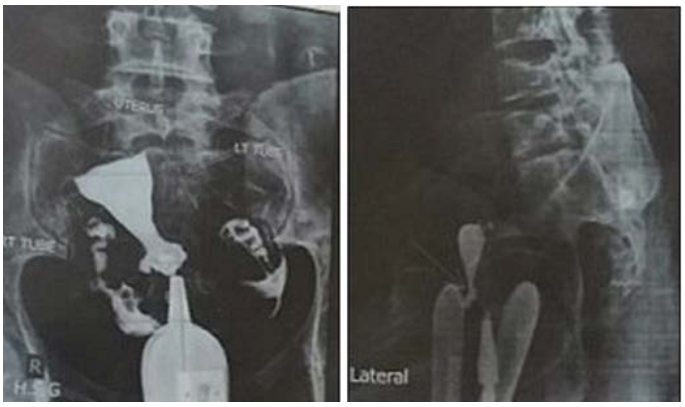

Magnetic resonance tomography is useful to measure the thickness of the lower uterine segment, the profundity of the isthmocele, and the substance of the endometrial and niche cavity. It permits the evaluation of other associated pathologies such as adenomyosis or adnexal, uterine, or pelvic diseases.

TREATMENTS

- A diversity of approaches include laparotomy, laparoscopy, hysteroscopy, vaginal repair, and several combined techniques with no statistically superior outcome noted in the literature. In that respect is no gold standard treatment for isthmocele.

- Medical treatment: Medical treatment is the best for women with isthmocele who do not desire to get pregnant seems to be oral contraception. Zhang et al[18] have published a survey on the role of oral contraceptives with estrogen and progesterone in 18 patients and have found it to be effective regarding the duration of flow (reducing from 10 days to 5 days). Other authors[19] have also described oral contraceptives to be efficacious in reducing bleeding disorders. Florio et al[20] have described less bleeding and less pain after the use of oral contraceptives or hysteroscopic resection with better results in women undergoing hysteroscopic correction compared with oral contraceptives. The usage of an intrauterine device with levonorgestrel has not shown a benefit in these women.[21]

- Vaginal Surgery: According to Zhang et al,[18] once the cervix was grasped by 2 forceps, diluted bovine pituitary hormones were injected subepithelially at the cervicovaginal junction to determine tissue planes and reduce minor bleeding. The incision was made where the hormone was injected, and the bladder was then deflected off the anterior cervix. Once identified at the uterine isthmus, the isthmocele was excised and fixed. Zhang[21] has reported no complications (14 patients). This technique requires surgical expertise to avoid damaging the surrounding organs. It also necessitates that the isthmocele is not too high or vaginal correction would be difficult. Outcomes show that menstruation duration diminishes after treatment[18] and myometrial thickness increases. Most patients experience symptom relief (reported between 85% and 93%) and modest if any complications after this surgical approach. Xie et al[22] and Zhang et al[21] have noted a resulting 22% pregnancy rate.

- Laparoscopic resection of niches: Excision of uterine sacculation (niche) with uterine reconstruction is a conservative surgical laparoscopic technique that should be studied by a selected group of patients in whom fertility sparing is desired. Laparoscopy is commonly guided by hysteroscopy. The surgical technique was identified as using carbon dioxide laser, the scar was opened from one terminal to the other, and fibrotic tissue was excised from the borders of the defect to access the healthy momentum. Before closure, a Hegar probe was introduced into the cervix to preserve the continuity of the cervical canal with the womb. Multiple layers of separate sutures were applied to attain double-layer closure, and the peritoneum was then concluded. The critical tone of this process is to correctly identify the isthmocele, which can be reached using the observing techniques: hysteroscopy to evaluate the uterine cavity and the defect; if the isthmocele is not identified by laparoscopy, hysteroscopy can be restated; and the tip light of the hysteroscopic instrument can be introduced into the shortcoming.[23]

- Hysteroscopy: Most authors treated symptomatic cesarean scar defects with hysteroscopy. Cervical dilation was performed using Hegar dilators (up>9) and the anterior and posterior edges of the defect were resected with a cutting loop and pure cutting current, followed by resection of the scar tissue at the apex of the niche. Scar tissue was completely removed using a resectoscopic loop until the muscular tissue below was evident. The entire fibrotic part of the scar should be removed and the muscular part has been reached.[24]

CONFLICT OF INTERESTS

We hold that we have no conflict of interests with any consistency.

REFERENCES

1. Gubbini G, Casadio P, Marra E. Resectoscopic correction of the "isthmocele" in women with postmenstrual abnormal uterine bleeding and secondary infertility. *J Minim Invasive Gynecol*. 2008; 15:172-175. doi: 10.1016/j.jmig.2007.10.004

2. Morris H. Surgical pathology of the lower uterine segment caesarean section scar: is the scar a source of clinical symptoms? *Int J Gynecol Pathol*. 1995; 14:16-20.

3. Wang CB, Chiu WW, Lee CY, Sun YL, Lin YH, Tseng CJ. Cesarean scar defect: correlation between cesarean section number, defect size, clinical symptoms uterine position. *Ultrasound Obstet Gynecol*. 2009; 34: 85-89. doi: 10.1002/uog.6405

4. Stewart KS, Evans TW. Recurrent bleeding from the lower segment scar–a late complication of caesarean section. *Br J Obstet Gynaecol.* 1975; 82: 682-686.

5. Bij de Vaate AJ, van der Voet LF, Naji O, et al. Prevalence, potential risk factors for development and symptoms related to the presence of uterine niches following cesarean section: Systematic review. *Ultrasound Obstet Gynecol*. 2014; 43: 372-382. doi: 10.1002/uog.13199

6. van der Voet LF, Vervoort AJ, Veersema S, BijdeVaate AJ, Brolmann HA, Huirne JA. Minimally invasive therapy for gynaecological symptoms related to a niche in the caesarean scar: A systematic review. *BJOG*. 2014;121: 145–156. doi: 10.1111/1471-0528.12537

7. Tower AM, Frishman GN. Cesarean scar defects: An unrecognized cause of abnormal uterine bleeding and other gynecologic complications. *J Minim Invasive Gynecol*. 2013; 20: 562-572. doi: 10.1016/j.jmig.2013.03.008

8. Robson SJ, de Costa CM. Thirty years of the World Health Organization's target caesarean section rate: Time to move on. *Med J Aust.* 2017; 206: 181-185.

9. Barber EL, Lundsberd L, Belanger K, Pettker CM, Funai EF, Illuzzi JL. Contributing indications to the rising cesarean delivery rate. *Obstet Gynecol*. 2011; 118: 29-38. doi: 10.1097%2FAOG.0b013e31821e5f65

10. Barros AJ, Santos IS, Matijasevich A, et al. Patterns of deliveries in a Brazilian birth cohort: Almost universal cesarean sections for the better-off. *Rev Saude Publica*. 2011; 45(4): 635-643.

11. Abdel-Tawab N, Oraby D, Hassanein N, El-Nakib S. Caesarean section deliveries in egypt: Trends, practices, perceptions and cost. April 2018.

12. Davis N, Long C. Use of caesarean sections growing at 'alarming' rate. The Guardian, International edition. 11 October, 2018.

13. Hayakawa H, Itakura A, Mitsui T, et al. Methods for myometrium closure and other factors impacting effects on cesarean section scars of the uterine segment detected by the ultrasonography. Acta Obstet Gynecol Scand. 2006; 85: 429-434. doi: 10.1080/00016340500430436

14. Tower AM, Frishman GN. Cesarean scar defects: An underrecognized cause of abnormal uterine bleeding and other gynecologic complications. *J Minim Invasive Gynecol*. 2013; 20: 562-572. doi: 10.1016/j.jmig.2013.03.008

15. Gubbini G, Centini G, Nascetti D, et al. Surgical hysteroscopic treatment of cesarean-induced isthmocele in restoring fertility: Prospectistudy. *J Minim Invasive Gynecol*. 2011; 18: 234-237. doi: 10.1016/j.jmig.2010.10.011

16. Tulandi T, Cohen A. Emerging manifestations of cesarean scar defect in reproductive-aged women. *J Minim Invasive Gynecol*. 2016; 23: 893-902. doi: 10.1016/j.jmig.2016.06.020

17. Wang CB, Chiu WW, Lee CY, Sun YL, Lin YH, Tseng CJ. Cesarean scar defect: correlation between Cesarean section number, defect size, clinical symptoms and uterine position. *Ultrasound Obstet Gynecol*. 2009; 34: 85-89. doi: 10.1002/uog.6405

18. Zhang X, Yang M, Wang Q, Chen J, Ding J, Hua K. Prospective evaluation of five methods used to treat cesarean scar defects. *Int J Gynaecol Obstet*. 2016; 134: 336-339. doi: 10.1016/j.ijgo.2016.04.011

19. Tahara M, Shimizu T, Shimoura H. Preliminary report of treatment with oral contraceptive pills for intermenstrual vaginal bleeding secondary to a cesarean section scar. *Fertil Steril*. 2006; 86: 477-479. doi: 10.1016/j.fertnstert.2006.01.020

20. Florio P, Gubbini G, Marra E, et al. A retrospective case-control

study comparing hysteroscopic resection versus hormonal modulation in treating menstrual disorders due to isthmocele. *Gynecol Endocrinol*. 2011; 27: 434-438. doi: 10.3109/09513590.2010.495431

21. Zhang Y. A comparative study of transvaginal repair and laparoscopic repair in the management of patients with previous cesarean scar defect. *J Minim Invasive Gynecol*. 2016; 23: 535-541. doi: 10.1016/j.jmig.2016.01.007

22. Xie H, Wu Y, Yu F, He M, Cao M, Yao S. A comparison of vaginal surgery and operative hysteroscopy for the treatment of cesarean induced isthmocele: A retrospective review. *Gynecol Obstet Invest*. 2014; 77: 78-83. doi: 10.1159/000356961

23. Donnez O, Donnez J, Orellana R, Dolmans MM. Gynecological and obstetrical outcomes after laparoscopic repair of a cesarean scar defect in a series of 38 women. *Fertil Steril*. 2017; 107(1): 289-296. doi: 10.1016/j.fertnstert.2016.09.033

24. Cohen SB, Mashiach R, Baron A, et al. Feasibility and efficacy of repeated hysteroscopic cesarean niche resection. *Eur J Obstet Gynecol Reprod Biol*. 2017; 217: 12-17. doi: 10.1016/j.ejogrb.2017.08.010